

Division of Aortic Leaflets

TELLTALE System

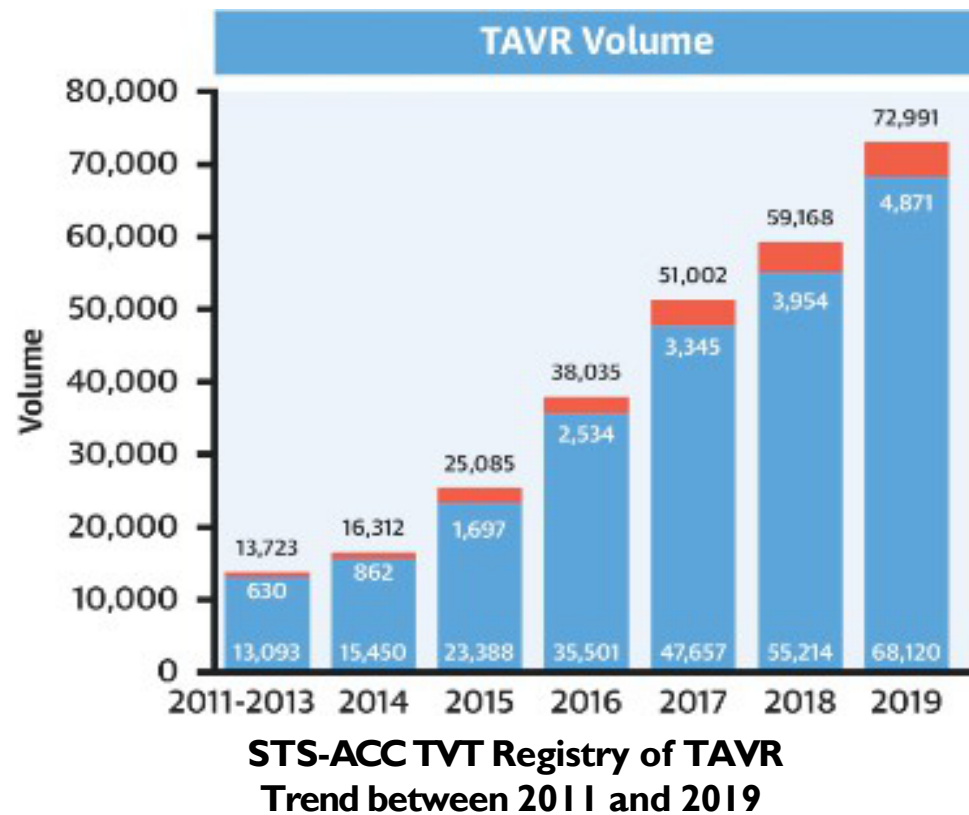
Transmural Electrosurgery LeafLet Traversal and Laceration Evaluation

Toby Rogers, MD

Interventional Cardiologist
Valvular & Structural Heart Disease
Medstar Washington Hospital Center

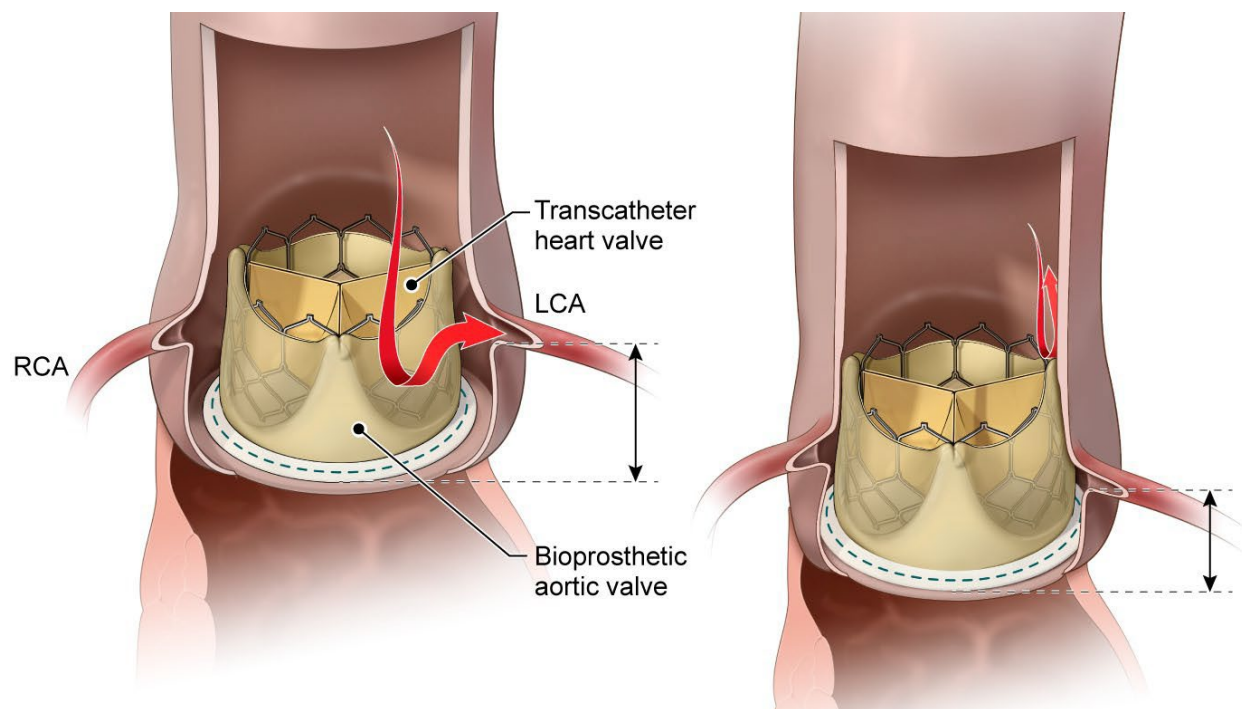
ICD-10 Coordination and Maintenance Committee Meeting
March 2025

Transcatheter Aortic Valve Replacement (TAVR) is the predominant aortic valve replacement strategy in the U.S. and the market continues to grow



*The size of the North American TAVR is forecasted to grow to **USD 2 billion by 2029** from USD 0.98 billion in 2024, growing at a CAGR of 16.8% between 2024 and 2029*

Coronary obstruction after TAVR is a **life-threatening emergency** with **>50%** inpatient mortality



No coronary obstruction

Coronary obstruction
From deficient sinus
or sinus sequestration

2 in every 100 patients undergoing TAVR for **native aortic stenosis** risks coronary obstruction

4 in every 100 patients undergoing TAVR for **SAVR failure** risks coronary obstruction

25 in every 100 patients undergoing TAVR for **TAVR failure** risks coronary obstruction

Currently available therapies to mitigate coronary obstruction have significant limitations

Leaflet modification *Off-label BASILICA*

- Radiofrequency leaflet laceration with off-label BASILICA **creates a splay** in the leaflet in front of the coronary ostium.
- Limited by the **absence of dedicated catheters** to easily and safely engage the target leaflets and by the **absence of dedicated electrosurgical devices**, optimized for electrical safety, to easily and safely traverse and lacerate leaflets.

“Snorkel” (or “Chimney”) stenting *Off-label, bail out*

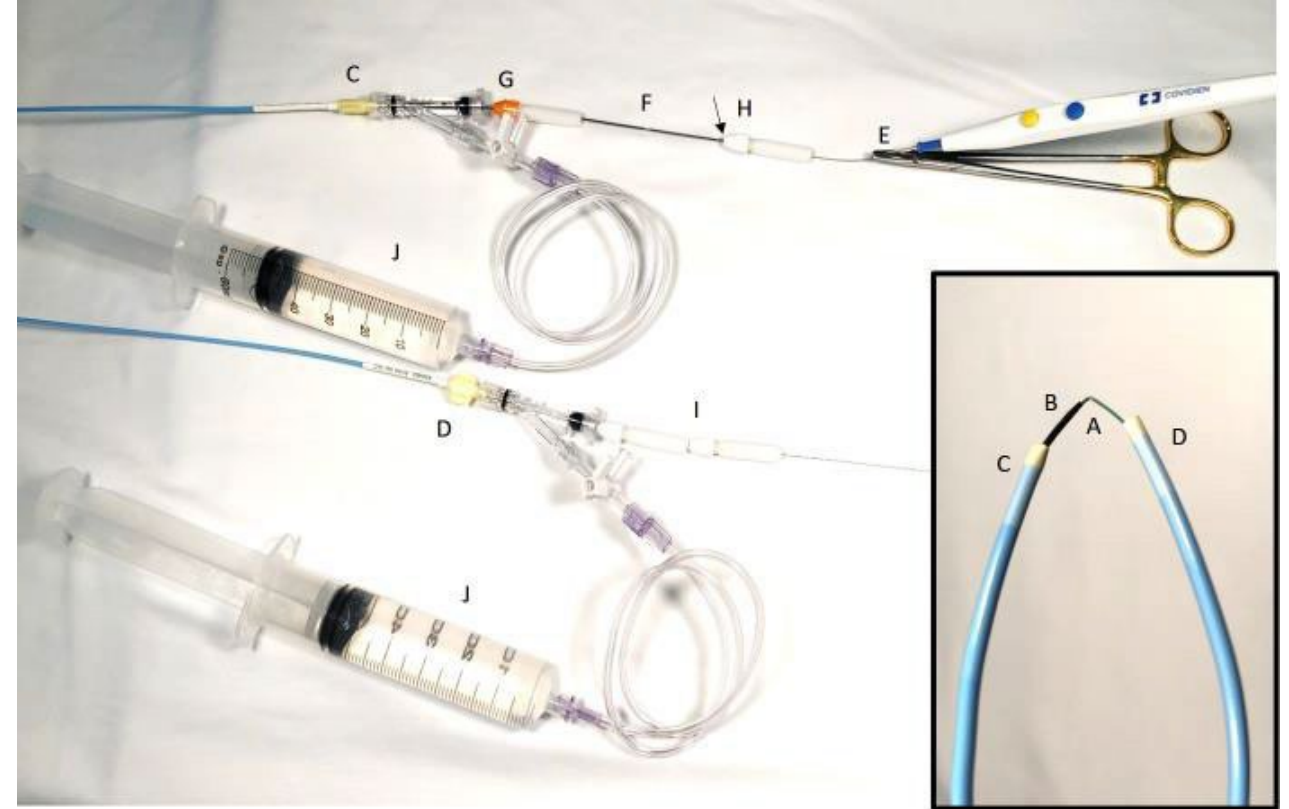
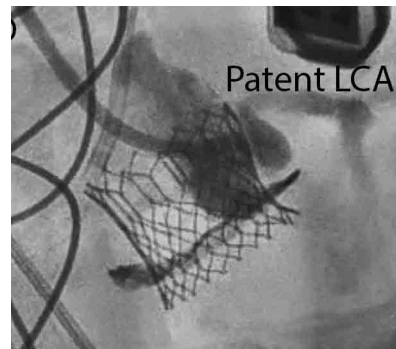
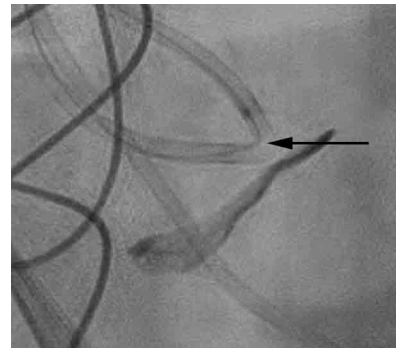
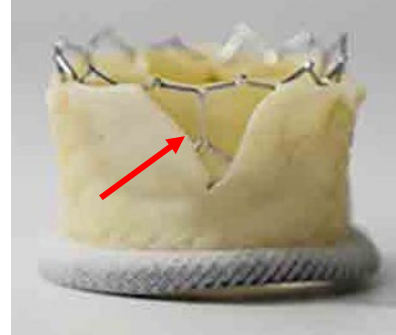
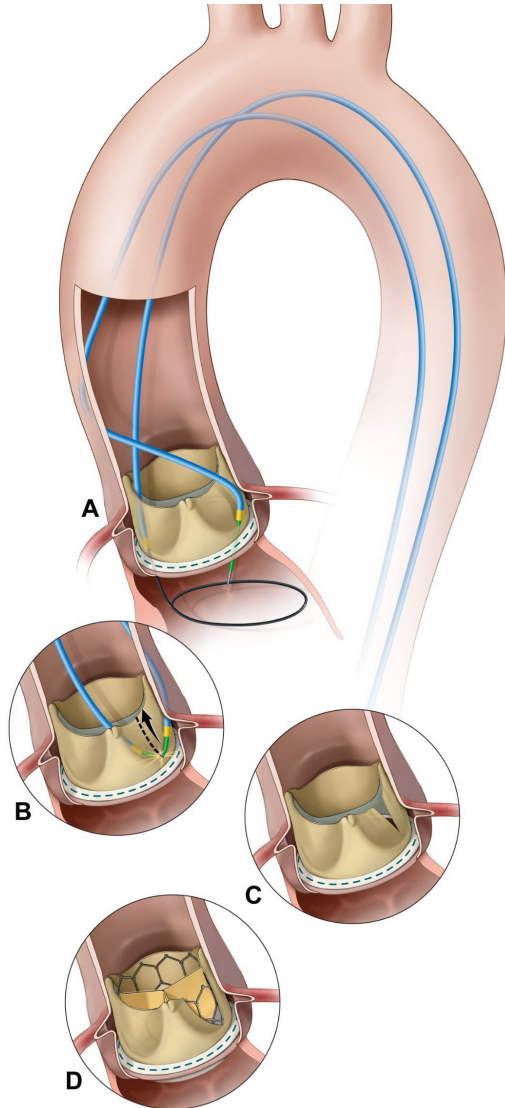
- Placement of a **coronary stent protruding from the coronary ostium** into the aorta and between the TAVR valve frame and the aortic wall.
- **Risks acute, subacute, and chronic complications** including stent compression, fracture, deformation, under-expansion, in-stent re-stenosis, late stent failure, stent thrombosis, and sinus thrombosis.
- **Challenging (if not impossible) re-access** to the coronary artery for PCI.

TAVR avoidance

- Alternative is **surgical explant** for low or intermediate risk patients.
- **Surgery not an option** for high or extreme risk patients, with expected 50% mortality within 1 year.

Radiofrequency leaflet laceration with off-label BASILICA

A creative solution but limited by absence of dedicated devices



*Cumbersome set-up using off-label equipment
(bedside modification of commercial devices)*

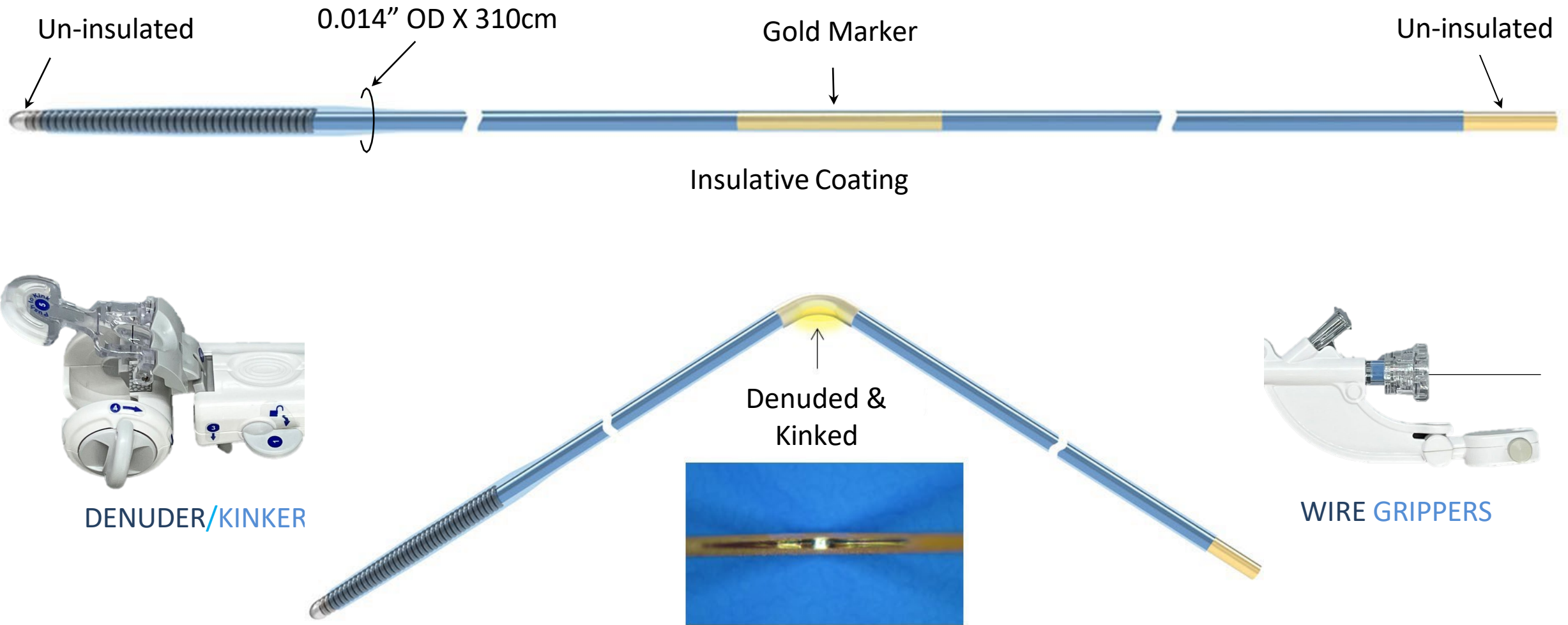
TELLTALE is the first dedicated electrosurgery guidewire for leaflet laceration – **reliable, fast, and safe**

- 1st dedicated 0.014” guidewire system for transcatheter electrosurgical laceration of valve tissue (native or bioprosthetic leaflet)
- Engineered for optimal radiofrequency energy delivery and electrical safety
 - Minimum force, minimal thermal injury, minimal damage to tissue
 - Reliable leaflet traversal and laceration
 - No bulky or sharp devices
- Transforms BASILICA into a fast, safe, and easy to disseminate procedure
- Granted Breakthrough Medical Device Status by the FDA on April 12, 2024.

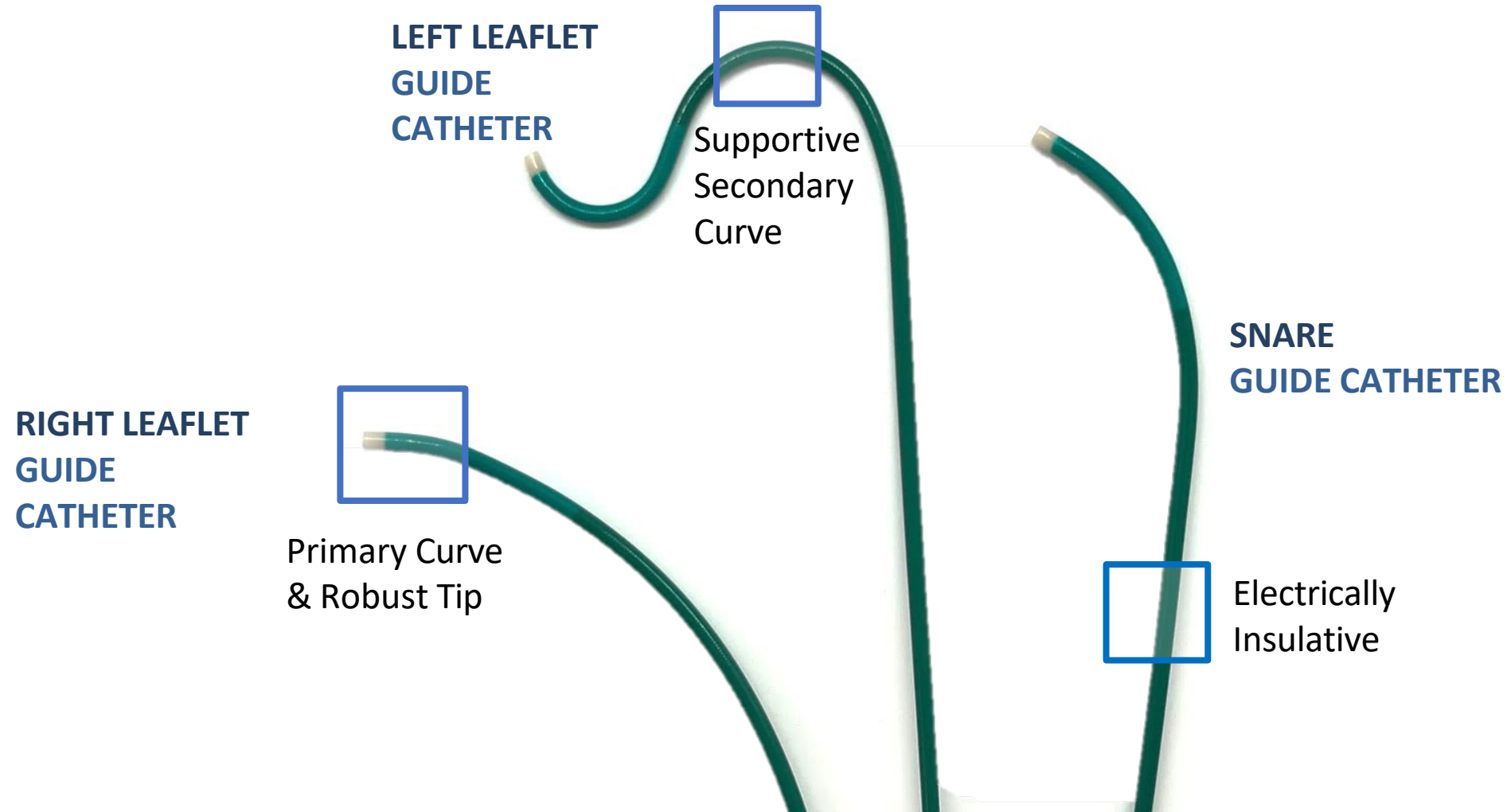
TELLTALE Indications for Use*

The TELLTALE Electrosurgical Guidewire System is indicated for transcatheter electrosurgical traversal and laceration of **native and bioprosthetic** tissue in patients at risk of coronary obstruction during TAVR.

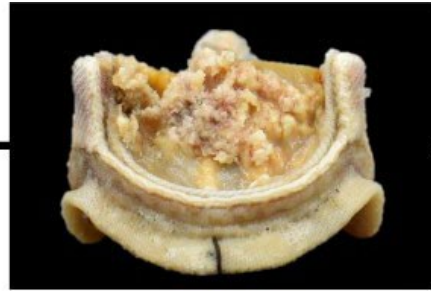
TELLTALE System



TELLTALE System: Pachyderm Guide Catheters



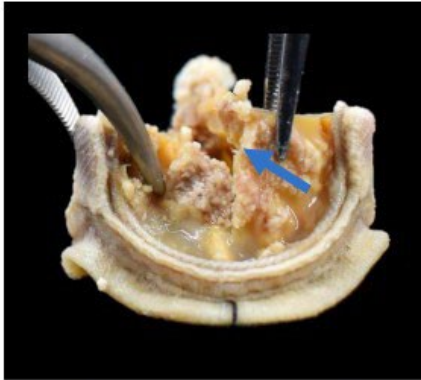
Mechanical versus electrosurgical leaflet cutting



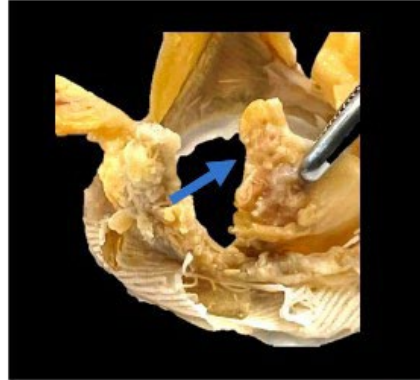
Explanted heavily calcified surgical bioprosthetic valve

Mechanical laceration

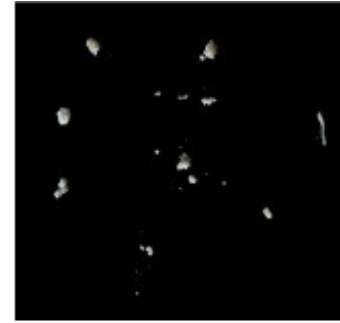
Electrical laceration



Torn leaflet following mechanical laceration



Clean linear cut following electrical laceration



Liberation of debris following mechanical laceration



Absence of debris generation following electrical laceration

CONCLUSIONS

Compared with mechanical cutting, electrosurgery may result in:

1. Fewer leaflet tears/avulsions, and
2. Less debris embolization

TELLTALE System Procedural Steps

- **Pre-procedural planning** with ECG-gated contrast enhanced CT to identify the leaflet at risk of coronary obstruction
- **Access site** same as TAVR (two femoral arterial sheaths and one venous introducer for temporary transvenous pacing)
- Procedure is completed under fluoroscopic guidance and transesophageal echocardiography (optional)
 - **Leaflet Traversal:**
 - A snare guide catheter with a gooseneck snare is placed under the valve in the LVOT
 - A traversal guide catheter is placed on the target aortic leaflet near the hinge point
 - TELLTALE guidewire is delivered through the traversal guide catheter
 - 15-20W of RF energy delivered to traverse through the base of the leaflet
 - Tip of guidewire is snared in the snare guide catheter in the LVOT

TELLTALE System Procedural Steps continued

- **Leaflet Laceration:**

- 1cm mid gold section is denuded and kinked creating the laceration section of the guidewire (Flying-V)
- Flying-V is advanced to the aortic cusp by externalizing the snare distal tip of guidewire
- Guide catheters are positioned at the radiopaque ends of the Flying-V and locked in place with guidewire grippers
- Proximal end of guidewire re-attached to generator and electrified at 30-40W under gentle tension to lacerate leaflet
- Split splays in systole and coapts in diastole, maintaining hemodynamic stability
- TELLTALE system removed from body

- **TAVR implant using standard technique**

- Coronary artery patency assessed using aortography or selective coronary angiography

Procedural Documentation

- Use of the TELLTALE system is documented in the Catheterization lab procedure report
- Leaflet laceration using the TELLTALE system may be referred to using various terms:
 - TELLTALE
 - TELLTALE System
 - TELLTALE Electrosurgical System
 - TELLTALE - BASILICA
 - BASILICA (Bioprosthetic or native aortic scallop intentional laceration to prevent iatrogenic coronary artery obstruction)
 - Leaflet modification
 - Leaflet traversal and laceration
 - Leaflet laceration
 - Energy-based leaflet laceration
 - Aortic valve laceration
 - Native aortic valve laceration
 - Bioprosthetic valve laceration
 - TELLTALE guidewire
 - Electrified guidewire
 - Pachyderm guide catheters
 - Denuder/kinker
 - Wire grippers

IDE Pivotal Study– Ongoing, 77 out of 90 patients enrolled (NCT05666713 sponsored by NHLBI)

Clinical Trial Design

Telltale is a Class II device (510K pathway)

Traversal and laceration of **native** and **bioprosthetic** aortic valve leaflets that threaten coronary obstruction during TAVR

- Prospective, multicenter, single arm, open-label
- 90-day follow up

Study population (n= 90)

- 60 bioprosthetic
- 30 native

Clinical Trial Endpoints

Primary efficacy endpoint: **technical success**

Primary safety endpoint: **inpatient safety**, composite of all-cause mortality, stroke, acute coronary artery obstruction, emergency cardiac surgery or re-intervention, and TELLTALE related complications

Secondary endpoint: **30-day safety** (freedom from MACE)

Summary

Growing leaflet modification market

TAVR is a market that will continue to grow

Number of failing transcatheter valves is expected to grow exponentially, many patients will require leaflet modification

Innovative technology to strengthen your structural heart portfolio

Simple, safe, and fast procedure that takes the guesswork out of electrosurgery

A system that includes an insulated 0.014" guidewire with optimized electrical and mechanical properties & support instruments

On-label indication promotes dissemination and proctorship

Questions?